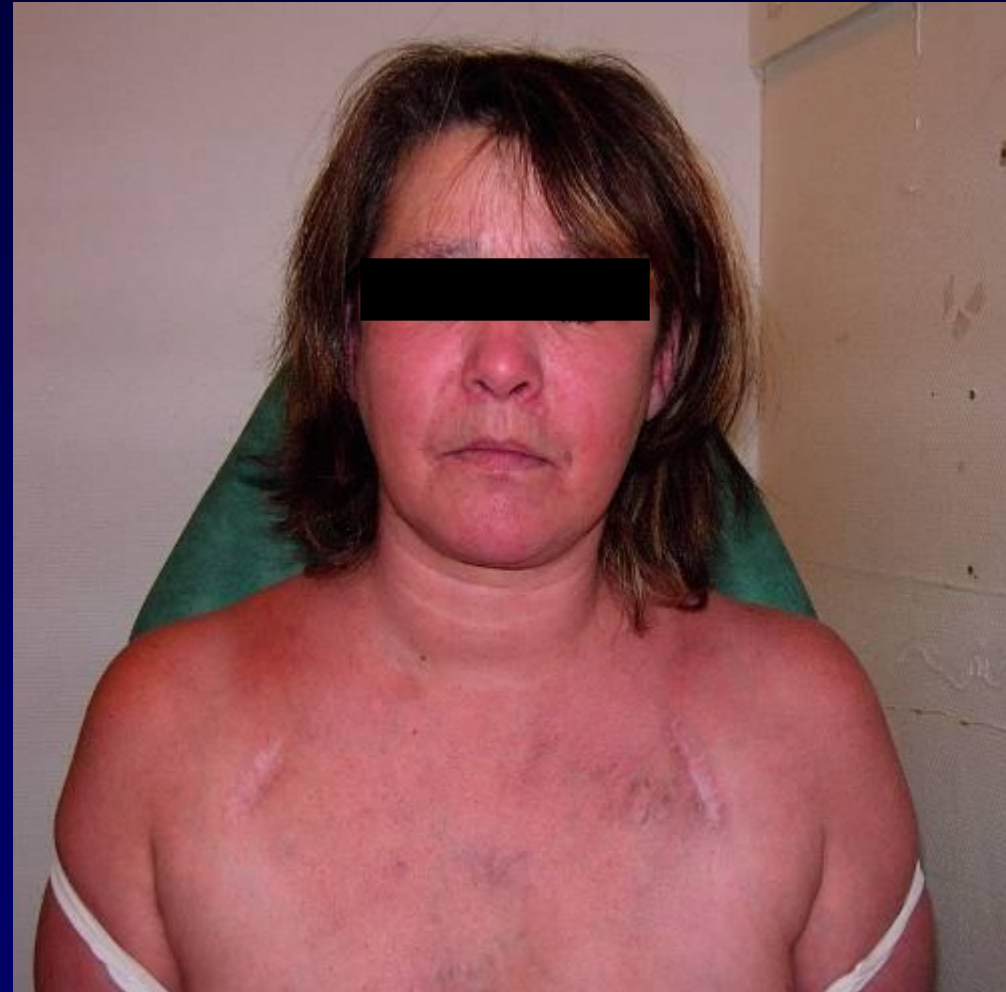

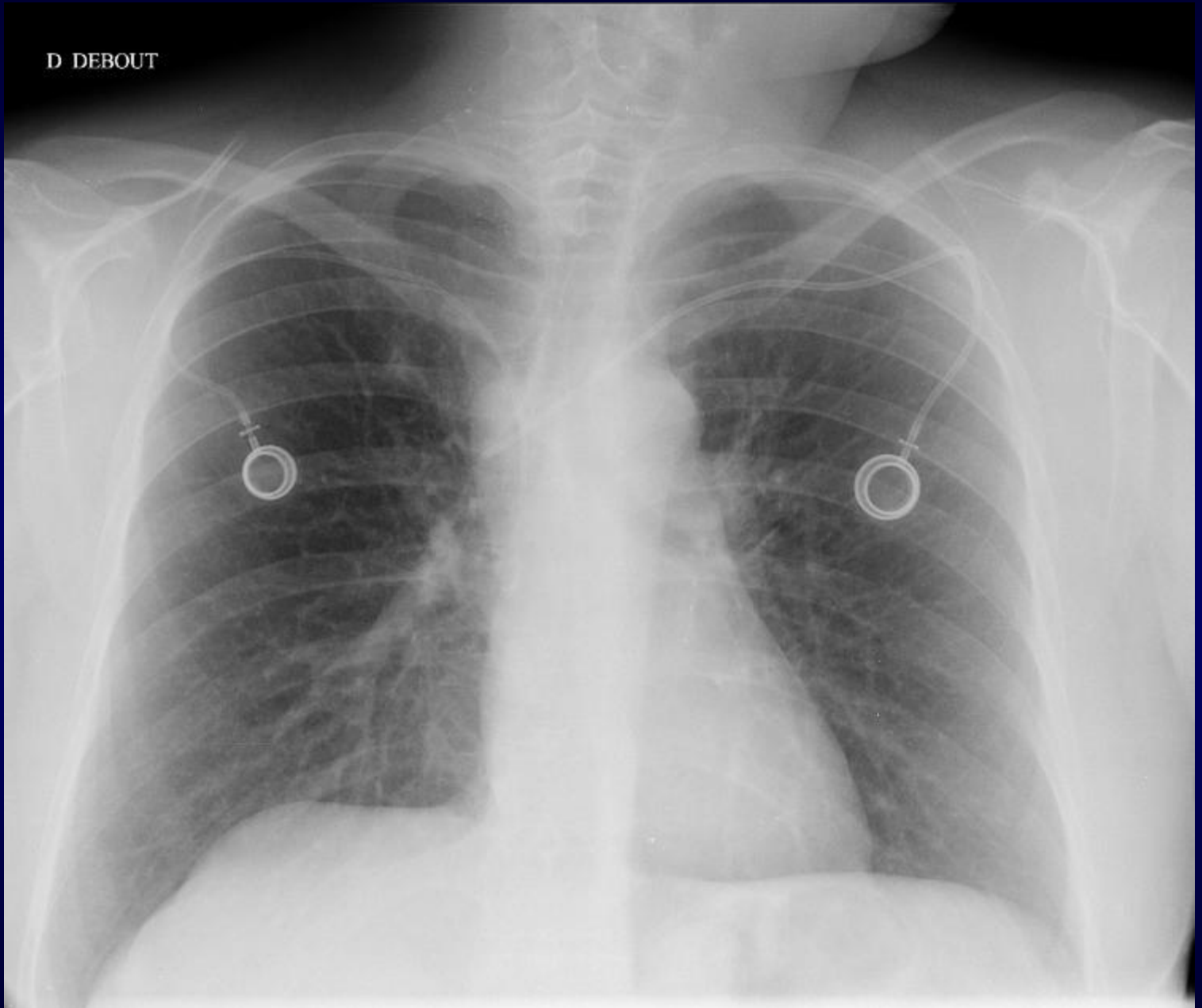


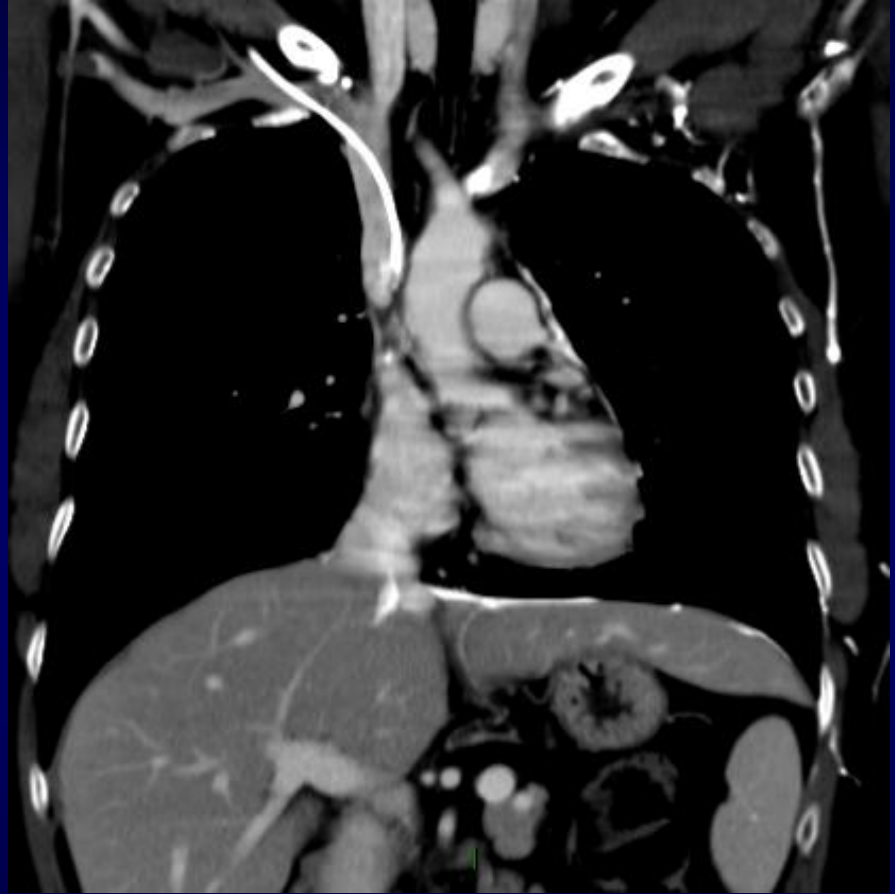
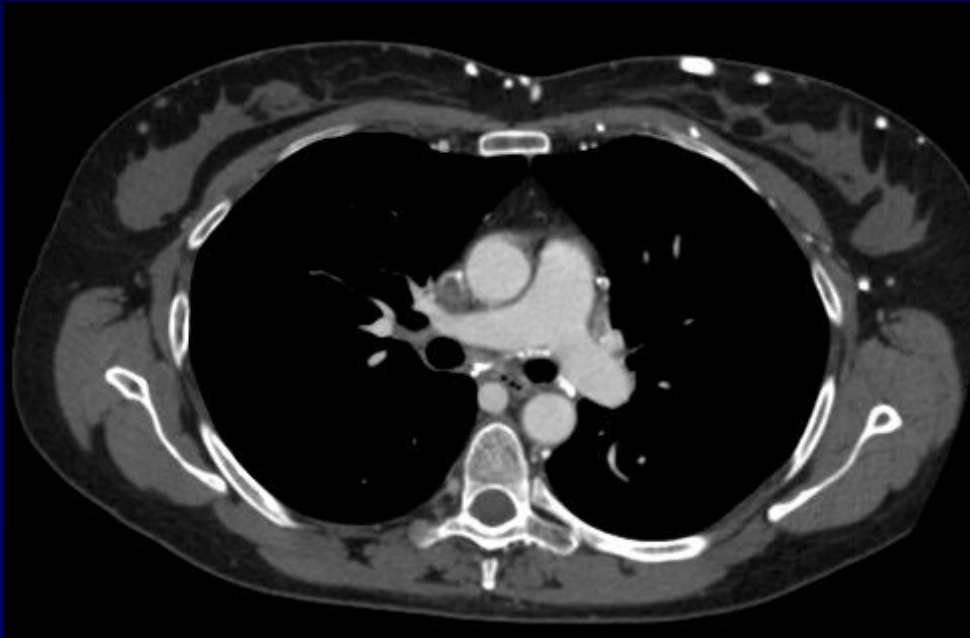
M EL HAJJAM
P LACOMBE

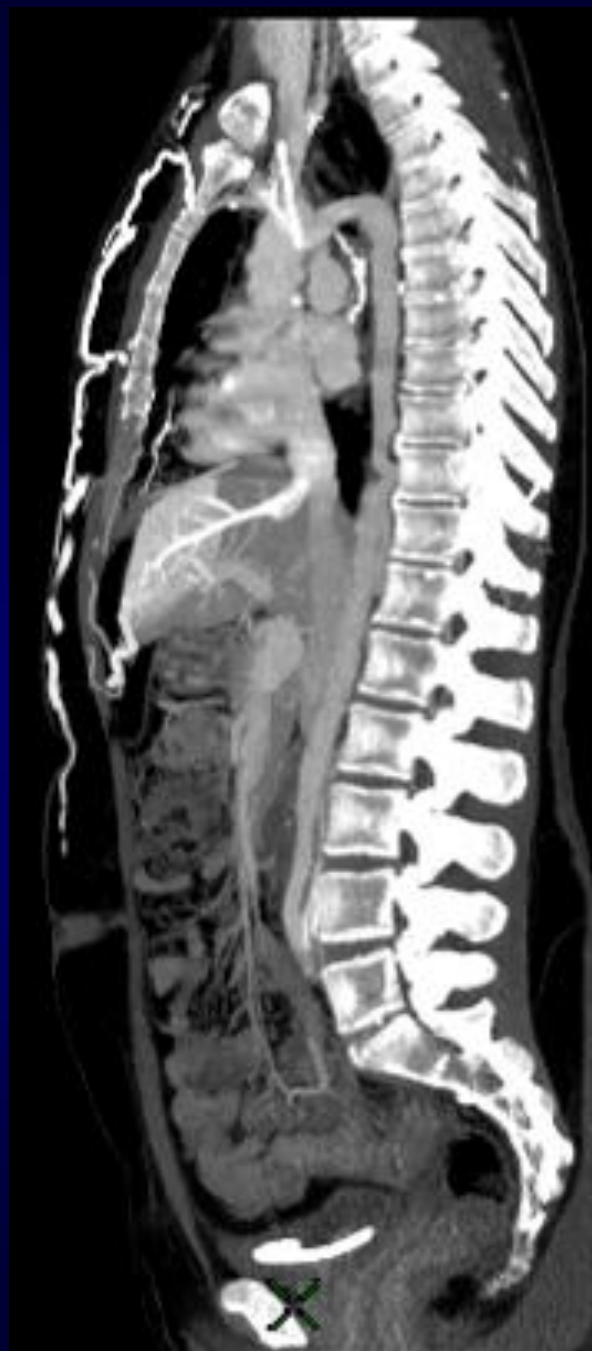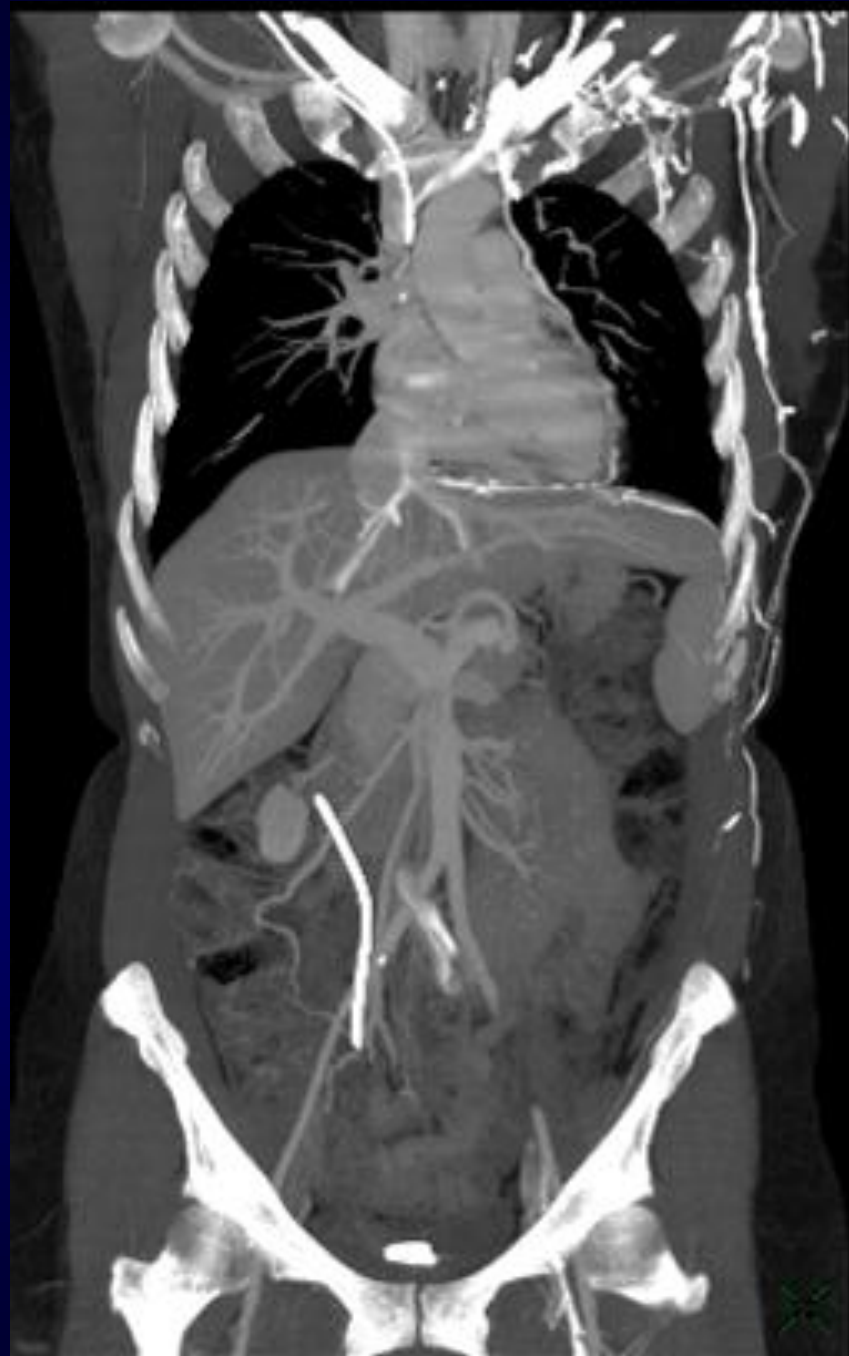Femme de 44 ans,
K rectum métastatique
Chirurgie
Chimiothérapie
Dysfonctionnement du DVI
Erythème facial

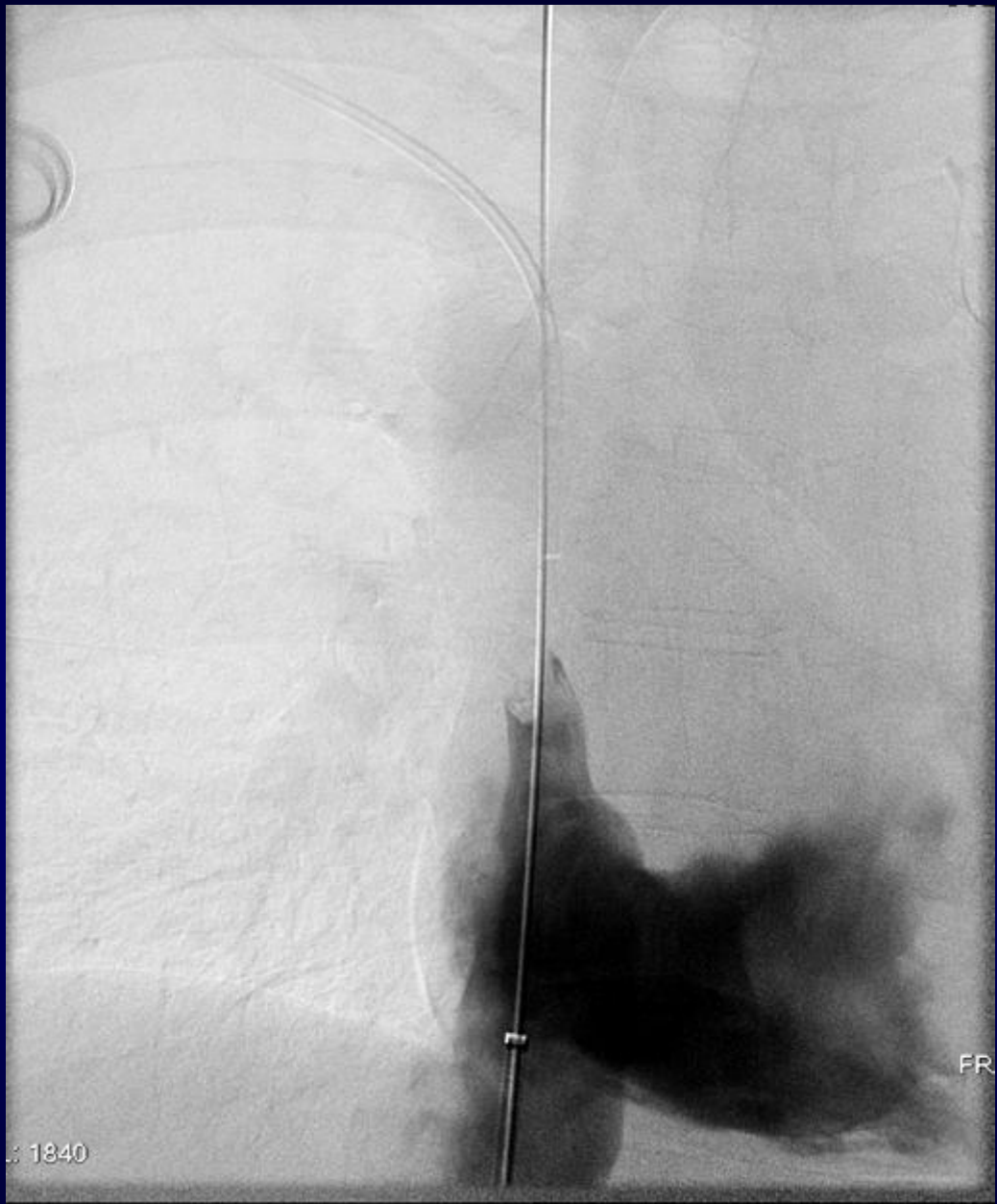


D DEBOUT









Cavographie

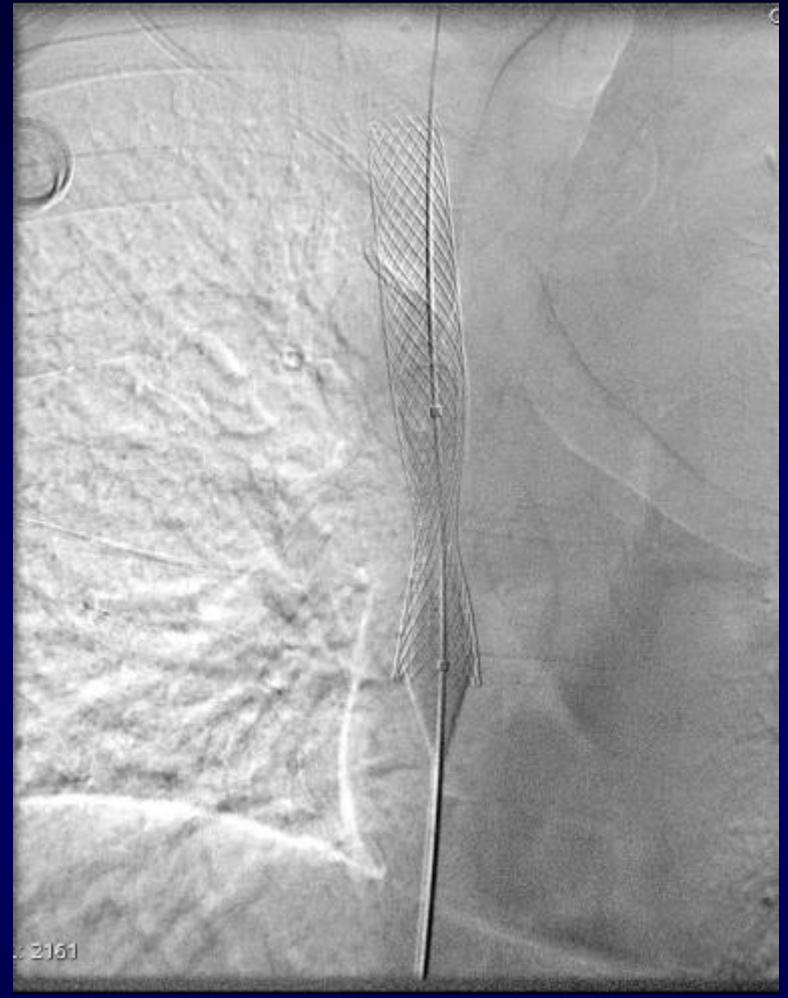
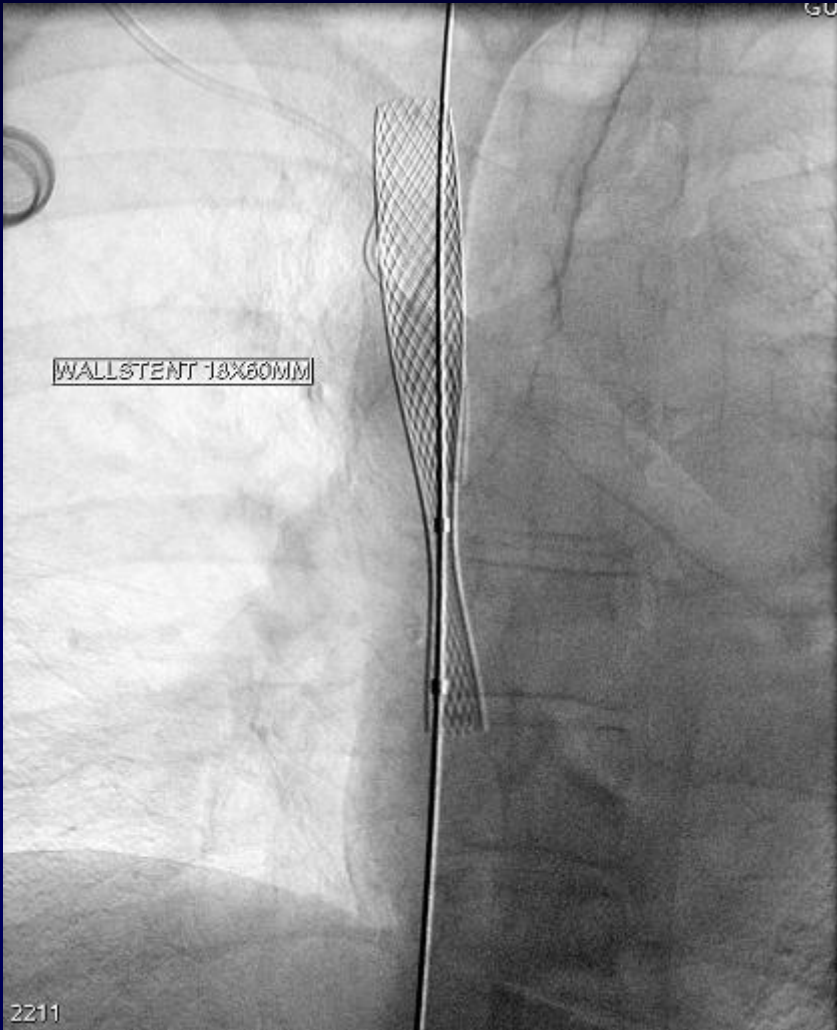
GU

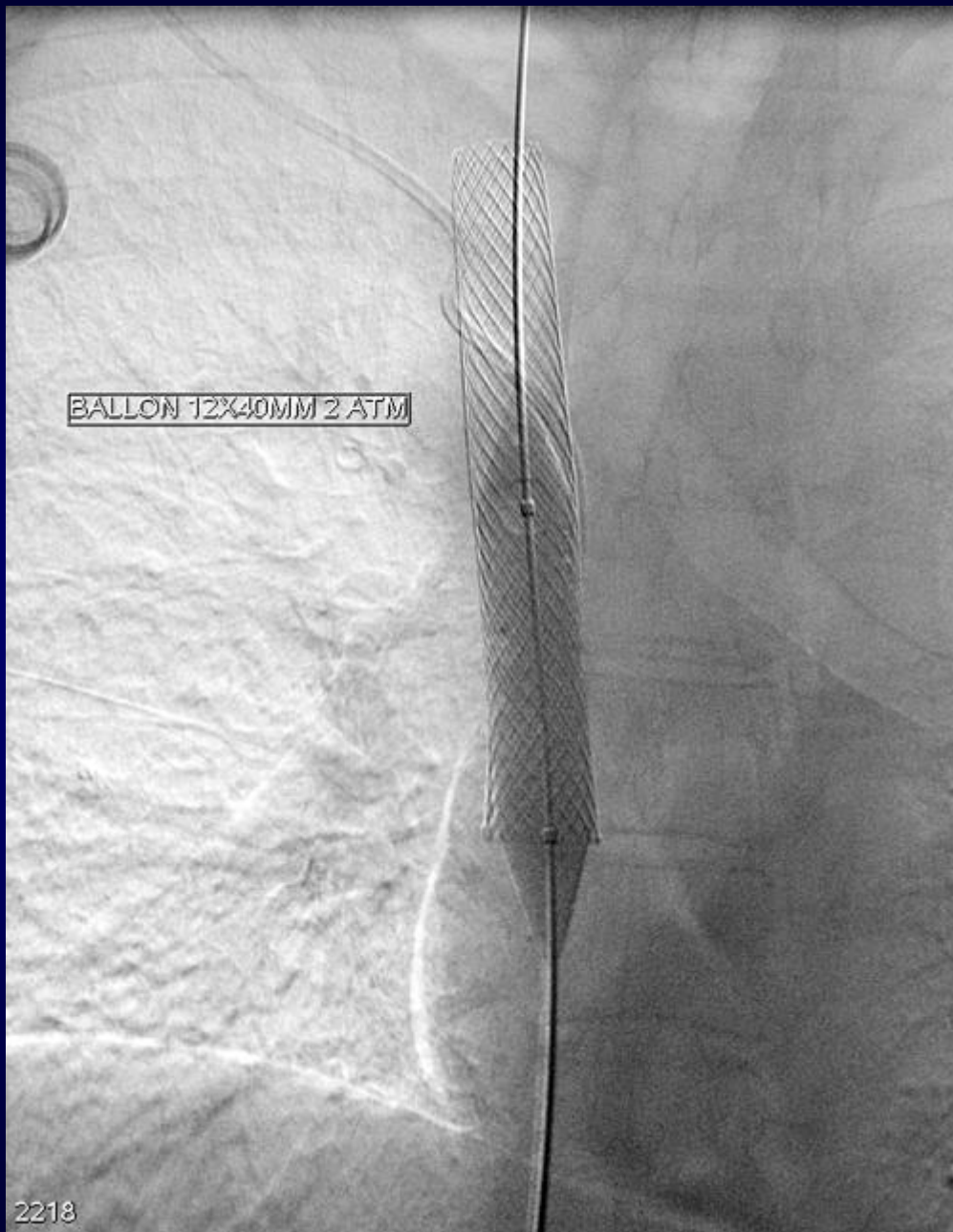
WALLSTENT 18X60MM

2211

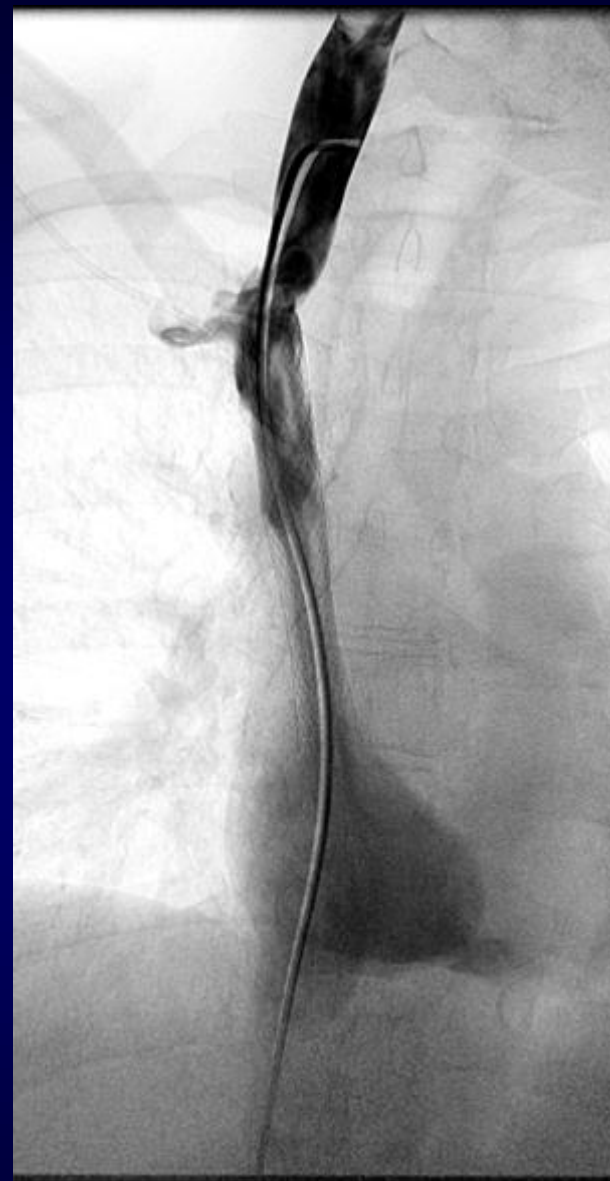
2161

GU





2218



Contrôle final

TDM contrôle à 1 mois

